

Surgical Management of Bladder Dysfunction in Multiple Sclerosis

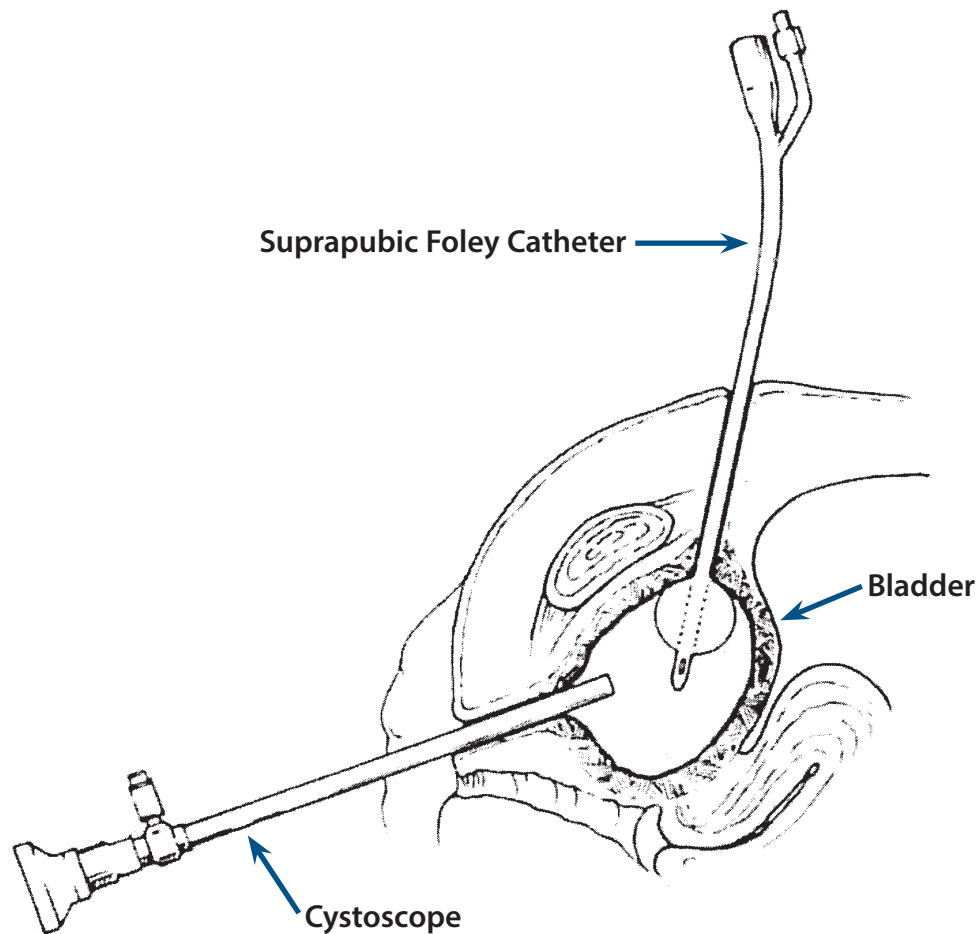
by *Scott E. Litwiler, MD and Susan J. Kalota, MD*

Over 80% of patients with multiple sclerosis (MS) have symptoms of lower genitourinary tract dysfunction. The effect of MS on the genitourinary tract ranges from bladder and sphincter dysfunction to impotence. These symptoms are often a major source of frustration and distress for patients. A team approach, involving the patient's treating neurologist, urologist, and rehabilitation specialist, is essential to optimizing patient care. For treatment purposes, patients may be separated into those with storage problems (detrusor hyper-reflexia), those with emptying problems (detrusor areflexia), and those with both (detrusor external sphincter dyssynergia—DESD). Past medical and surgical history is especially important in the MS patient, since competing pathologies may have an impact on lower urinary tract dysfunction. In most patients, conservative measures are an effective means of primary management. These measures, as described in the Clinical Bulletin on Urinary Dysfunction in Multiple Sclerosis, include anticholinergic medications and intermittent catheterization, depending upon the etiology.

When conservative measures fail in the treatment of lower genitourinary dysfunction, more aggressive options may be entertained. Surgical options include: suprapubic cystostomy; augmentation cystoplasty (surgical enlargement using an intestinal patch) with or without a catheterizable limb; incontinent ileovesicostomy; sphincterotomy; sphincteric stents; sacral nerve stimulation. Non-surgical procedures include transurethral bulking agent injections and botulinum toxin injections.

SURGICAL PROCEDURES

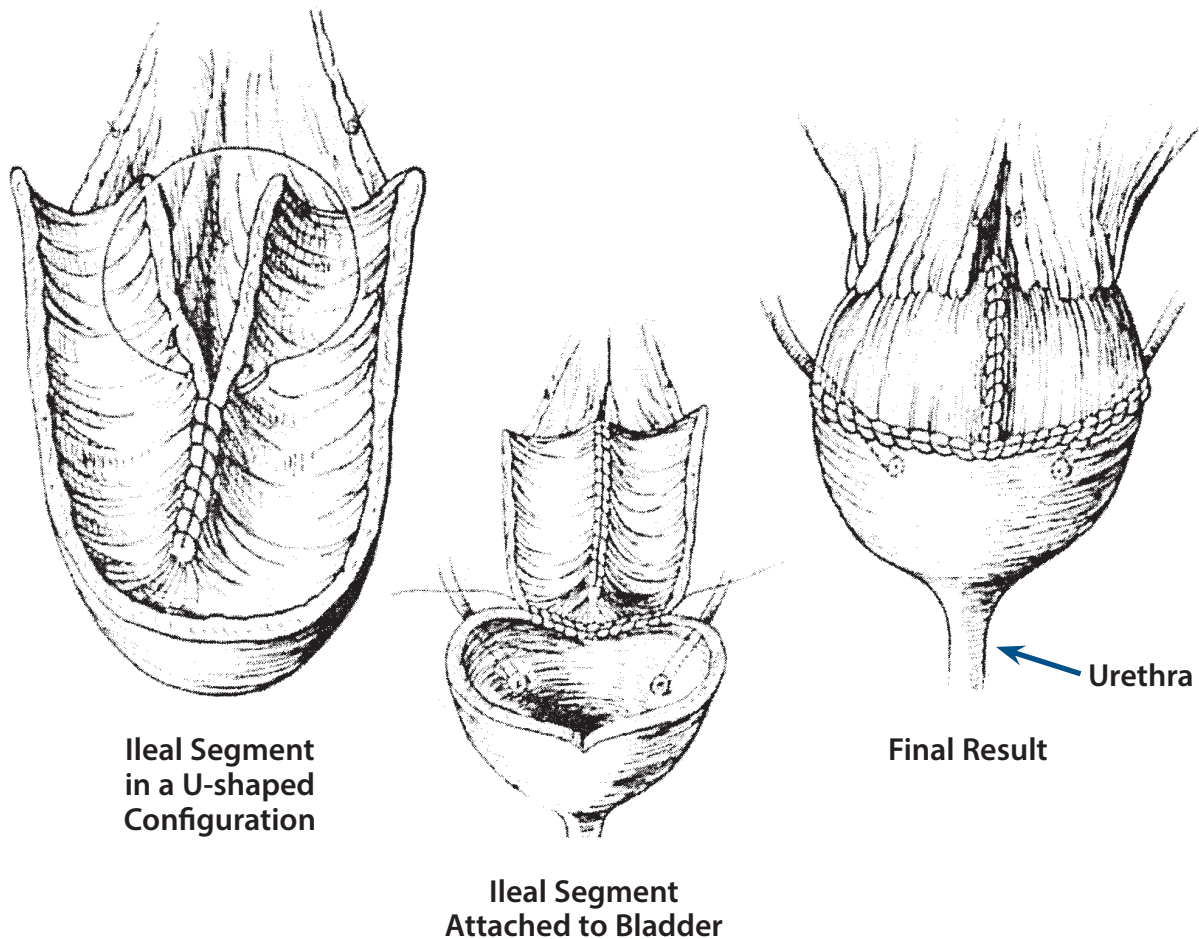
- ◆ **Suprapubic cystostomy** (Fig. 1) is a surgically-created channel in the abdominal wall directly into the bladder. Urine is eliminated from the bladder through a drainage tube (SP tube) into an external collection bag. This procedure avoids some of the potential complications of an indwelling catheter, such as traumatic urethral erosion. Personal hygiene and catheter care are simplified because catheter position is readily accessible and remote from vaginal and perineal soilage. However, the suprapubic cystostomy may not be a good long-term option

FIGURE 1 Suprapubic (SP) Tube: Placed Percutaneously Using Cystoscope

(Urologic Clinics of North America 1993; 20:3)

for younger patients because of the risk of bladder calculi, infection, and the rare development of squamous cell carcinoma.

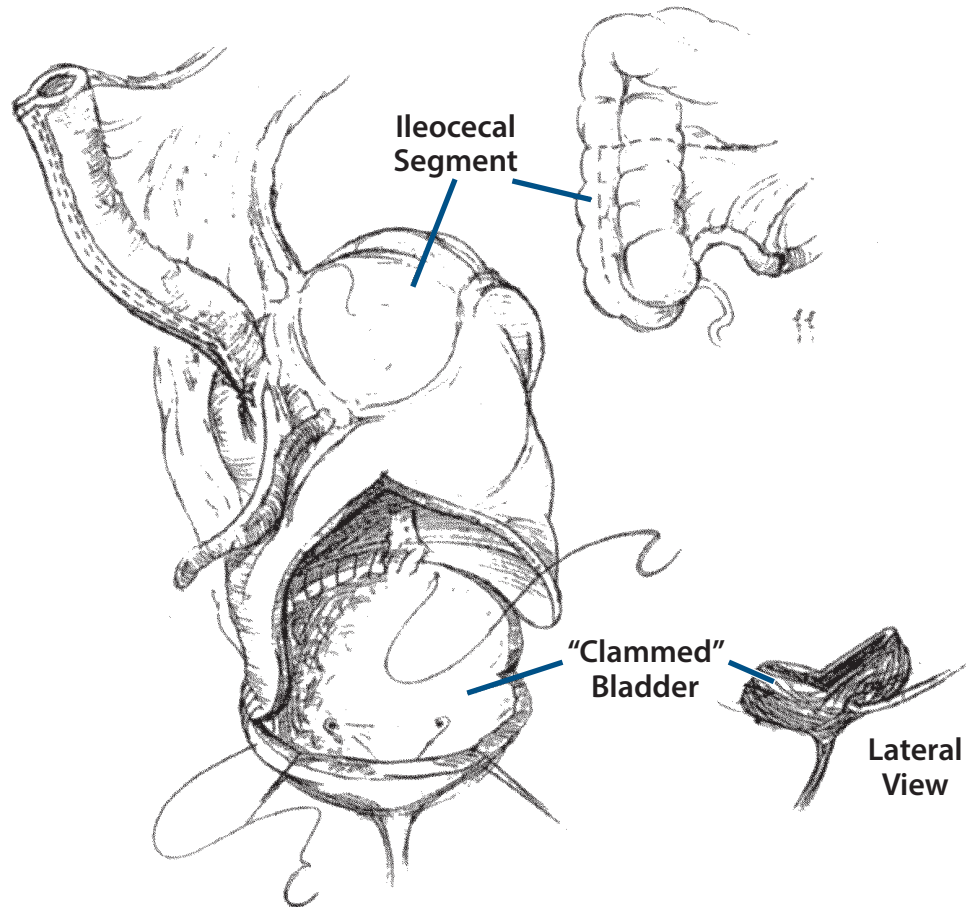
- ◆ **Augmentation cystoplasty** (Fig. 2) uses an ileocecal segment to augment existing bladder capacity and may also serve as a catheterizable abdominal stoma (Fig. 3). This procedure is usually reserved for the patient with detrusor hyper-reflexia (storage dysfunction), in whom all other conservative options have been exhausted. Some manual dexterity is required, but catheterization via the stoma is easier than urethral catheterization for the patient who uses a wheelchair for mobility, the patient with lower extremity spasticity, and the patient with poor dexterity.
- ◆ **Incontinent ileovesicostomy** (Fig. 4) is used when the client, family member, or caretaker cannot perform intermittent catheterization and conservative management has failed. In this procedure, a segment of ileum is used to augment the bladder, so that it may be tubularized

FIGURE 2 Augmentation Cystoplasty

(*Urologic Clinics of North America* 1993; 20:3)

and brought to the abdominal wall. The bladder is allowed to drain freely and a collection device is applied to the skin.

- ◆ **Sphincterotomy** entails endoscopically cutting the external sphincter in male patients with detrusor hyperactivity and DESD. Alternately a **urethral stent** may be placed to facilitate bladder emptying. In both treatment options, a condom catheter is necessary to manage the resulting incontinence. These procedures are best reserved for the patient with limited hand function for whom intermittent catheterization is not an option.
- ◆ **Sacral nerve stimulation** (InterStim Therapy for Urinary Control) is a permanent procedure for people with severe urge incontinence. InterStim utilizes a surgically-implanted stimulator to provide continual sacral nerve stimulation to inhibit excessive bladder (detrusor muscle) contractions. Rare side effects include pain and infection, which may necessitate removal of the device. An MRI is contraindicated with the stimulator in place, which may limit its applicability for people with MS.

FIGURE 3 Augmentation Cystoplasty with Catheterizable Stoma

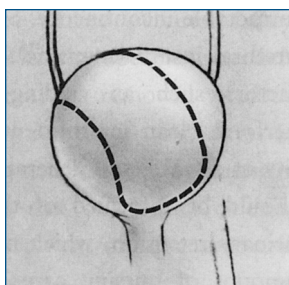
(From Sutton et al., 1998)

NON-SURGICAL INTERVENTIONS

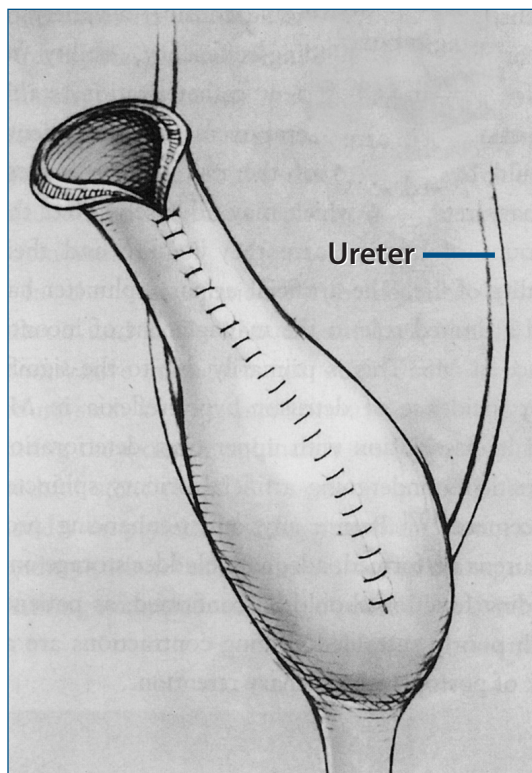
Non-surgical interventions for DESD and detrusor hyper-reflexia include pharmacologic therapy to suppress uninhibited bladder contractions (e.g., tolterodine, oxybutynin) or decrease the production of urine (e.g., desmopressin), a variety of intravesical medications (e.g., capsaicin, oxybutynin, etc.), and botulinum toxin injections.

- ◆ **Botulinum toxin** (Botox) can be useful in the management of DESD and detrusor hyper-reflexia. In a number of studies, botulinum toxin, injected into the external sphincter of the bladder, improved voiding symptoms and urodynamic measurements. Treatment benefits last a minimum of three months. No significant complications or side effects have been reported. The objection to this treatment is its cost. A vial of botulinum toxin costs over \$400 for 100 units of the drug. A single bladder procedure can use one to three vials. The development of anti-botox antibodies potentially may limit the effectiveness of this procedure.

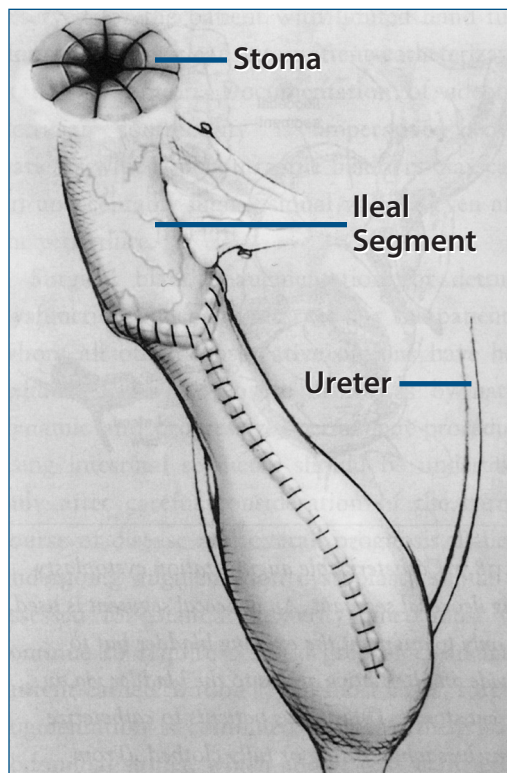
FIGURE 4 Ileovesicostomy



**Bladder
Before Surgery**



Elongated Bladder



Elongated with Ileal Segment Added

(From Litwiller, 2003)

The treatment for urethral incompetence includes the use of injectable bulking agents, urethral inserts, conventional bladder suspension procedures, and compressive slings.

- ◆ Currently available bulking agents are Macroplastique and Coaptite. Injections around the urethra at the bladder neck can relieve incontinence due to intrinsic sphincter deficiency or type III stress incontinence. The bulking agent serves to improve urethral function. This procedure, which may need to be repeated periodically, has been shown to work more effectively in women than in men, but success rates are low and it is very expensive.

Healthcare professionals are often asked about the advisability of pursuing these more aggressive treatment options. Patients should be encouraged to discuss the decision with the neurologist and obtain a second opinion from a urologist with expertise in the care of people with MS.

PATIENT SELECTION CRITERIA

As described in Part I, most types of bladder dysfunction will respond well to conservative treatment measures, particularly if begun early, before more serious problems have arisen. The options described here should generally be considered only for those patients in whom the more conservative measures have not been successful. Being able to document a conservative progression of interventions will make it easier to obtain insurance coverage should surgical procedures become necessary.

To ensure the safety and success of complex surgical procedures, it is important to screen patients carefully. Treatment decisions should take into account the patient's weight and physique, level of disability and ability to function independently, cognitive impairment, manual dexterity, concurrent medical problems, social support networks, life expectancy of an additional 20 years or more, and urodynamic parameters. Only those who are able to comply reliably with the treatment plan—e.g., understand and follow instructions for self-care, keep scheduled appointments, commit to life-long follow-up—should be considered suitable candidates.

EMOTIONAL FACTORS

MS-related elimination problems are a threat to self-esteem, as well as a person's sense of confidence and autonomy. No person finds it easy to accept loss of control over bodily functions. For those who have mastered and adjusted to intermittent self-catheterization, only to reach a point that it no longer suffices to solve the problem, the threat to self-esteem is renewed. Those who have never experienced success with bladder control have probably lived for some time with anxiety, embarrassment, incontinence, pads or diapers, and an ongoing reluctance to drink fluids.

Surgical interventions bring both a sense of relief and additional emotional challenges. For most, the freedom from pads and diapers and the ability to drink freely again outweigh all other considerations. They feel in control of their bodies in a way that they have not for some time. Nonetheless, the surgical procedures require a period of adjustment as the person gradually alters his or her body image to incorporate the opening in the abdomen, the collection bag, or the catheterizable stoma. This adjustment process will be facilitated by adequate education and

discussion prior to the procedure, including the importance of realistic expectations and compliance with the recommended management regimen.

Regardless of a person's disability level, issues relating to self-esteem, self-image, and personal vanity remain important. Interventions that allow the person to feel good about his or her body are likely to be the most successful.

RECOMMENDED READINGS

- Anger JT, Weinberg A, Suttrop MJ, Litwin MS, Shekelle PG. Outcomes of intravesical botulinum toxin for idiopathic overactive bladder symptoms: A systematic review of the literature. *J Urol* 2010 Jun; 183(6): 2258–2264. Epub 2010 Apr 18.
- De Sese M, Raibouit P, Gallien P, Evsen-Schneider A, Denys P, Bonniaud V, Game X, Amarenco G. Transcutaneous posterior tibial nerve stimulations for treatment of the overactive bladder syndrome in multiple sclerosis: Results of a multicenter prospective study. *Neurourol Urodyn* 2011 Mar; 30(3): 306–311. doi: 10.1002/nau.20958. Epub 2011 Feb 8.
- Harper J, Holland NJ (eds). *Comprehensive nursing care in multiple sclerosis*, 3rd ed. New York: Springer Publishing Company, 2011.
- Holland NJ, Reitman NC. Bladder dysfunction in multiple sclerosis. *Clin Bull Natl MS Soc*, 2012. Available at <http://www.nationalmssociety.org/for-professionals/healthcare-professionals/publications/clinical-bulletins/index.aspx>.
- Karsenty G, Denys P, Amarenco G, De Seze M, Game X, Haab F, Kerdraon J, Perrouin-Verbe B, Ruffion A, Saussine C, Soler JM, Schurch B, Chartier-Kastler E. Botulinum toxin A (Botox) intradetrusor injections in adults with neurogenic detrusor overactivity/neurogenic overactive bladder: A systematic literature review. *Eur Urol* 2008 Feb; 53(2): 275–287. Epub 2007 Oct 16.
- Khan S, Game X, Kalsi V, Gonzales G, Panicker J, Elneil S, Apostolidis A, Hamid R, Dasgupta P, Kessler TM, Fowler CJ. Long-term effect on quality of life of repeat detrusor injections of botulinum neurotoxin-A for detrusor overactivity in patients with multiple sclerosis. *J Urol* 2011 Apr; 185(4): 1344–1349. Epub 2011 Feb 22.
- Legrand G, Rouprêt M, Comperat E, Even-Schneider A, Denys P, Chartier-Kastler E. Functional outcomes after management of end-stage neurological bladder dysfunction with ileal conduit in multiple sclerosis population: A monocentric experience. *Urology* 2011 Oct; 78(4): 937–941. Epub 2011 Aug 5.
- Litwiller SE. Management of bladder and sexual dysfunction in multiple sclerosis. In Cohen JA, Rudick RA (eds): *Multiple sclerosis therapeutics*, 4th ed. New York: Cambridge University Press, 2011.
- Multiple Sclerosis Council for Clinical Practice Guidelines. *Urinary dysfunction and multiple sclerosis*. Washington, DC: Paralyzed Veterans of America, 1999.
- Namey MA. Management of elimination dysfunction. In Halper J, Holland NJ (eds): *Comprehensive nursing care in multiple sclerosis*, 3rd ed. New York: Springer Publishing Company, 2011: 87–107.

- Oerlemans DJ, van Kerrebroeck PE. Sacral nerve stimulation for neuromodulation of the lower urinary tract. *Neurourol Urodyn* 2008; 27(1): 28–33.
- Schapiro RT. *Managing the symptoms of multiple sclerosis*, 5th ed. New York: Demos Medical Publishing, 2007.
- Stoffel JT. Contemporary management of the neurogenic bladder for multiple sclerosis patients. *Urol Clin North Am* 2010 Nov; 37(4): 547–557.
- Sutton MA, Hinsien JL, Nickell KG, Boone TB. Continent ileocecal augmentation cystoscopy. *Spinal Cord* 1998; 36: 246–251.